# Metaplastic Breast Carcinoma

## Update on Histopathology and Molecular Alterations

*Emily R. McMullen, MD; Nicholas A. Zoumberos, MD; Celina G. Kleer, MD*

• ***Context*—Metaplastic carcinoma is a rare, triple-negative carcinoma of the breast that exhibits transformation of part or all of its glandular carcinomatous component into a nonglandular, or metaplastic, component. The World Health Organization currently recognizes 5 variants of metaplastic carcinoma based on their histologic appearance.**

***Objective*—To review the histologic classifications, differential diagnosis, prognosis, and recent laboratory studies of metaplastic breast carcinoma.**

***Data Sources*.—We reviewed recently published studies that collectively examine metaplastic carcinomas, including results from our own research.**

***Conclusions*.—Metaplastic breast carcinoma has a broad spectrum of histologic patterns, often leading to a broad differential diagnosis. Diagnosis can typically be rendered by a combination of morphology and immunohistochemical staining for high-molecular-weight cytokeratins and p63. Recent studies elucidate new genes and pathways involved in the pathogenesis of metaplastic carcinoma, including the downregulation of *CCN6* and *WNT* pathway gene mutations, and provide a novel MMTV-Cre;*Ccn6*$^{fl/fl}$ knockout disease-relevant mouse model to test new therapies.**

**(*Arch Pathol Lab Med*. 2019;143:1492–1496; doi: 10.5858/arpa.2019-0396-RA)**

Metaplastic carcinoma, a subtype of triple-negative breast cancer, accounts for approximately 1% of breast tumors. These tumors have unique pathologic features, as their glandular component may be partially or totally replaced by a nonglandular component(s), which may differentiate along squamous, spindle, chondroid, and other lineages.[1,2] The histologic variants of metaplastic carcinoma depend on characteristics of the metaplastic component(s). At present, the molecular drivers for these tumors are far from understood, and there are limited therapeutic options. In this review, we discuss the broad spectrum of histologic findings, ancillary studies, and differential diagnosis. We also draw upon selected studies that elucidate the molecular alterations in metaplastic carcinomas, which not only advance the knowledge of the disease but also provide new biomarkers and possible targets of therapy.

Accepted for publication August 6, 2019.

From the Department of Pathology (Drs McMullen, Zoumberos, and Kleer) and Rogel Cancer Center (Dr Kleer), University of Michigan Medical School, Ann Arbor.

The authors have no relevant financial interest in the products or companies described in this article.

Presented in part at the New Frontiers in Pathology meeting; September 27–29, 2018; Ann Arbor, Michigan.

Corresponding author: Celina G. Kleer, MD, Department of Pathology, University of Michigan Medical School, 4217 Rogel Cancer Center, 1500 E Medical Center Dr, Ann Arbor, MI 48109 (email: kleer@umich.edu).

### METAPLASTIC CARCINOMAS ARE HISTOLOGICALLY HETEROGENEOUS AND COMPRISE LOW- AND HIGH-GRADE VARIANTS

An important aspect of this review is to highlight that metaplastic carcinomas are morphologically heterogeneous and comprise low- and high-grade tumors. The current World Health Organization (WHO) classification system for these tumors includes low-grade adenosquamous carcinoma, fibromatosis-like metaplastic carcinoma, squamous cell carcinoma, spindle cell carcinoma, and carcinoma with mesenchymal differentiation.[3] With the exception of low-grade adenosquamous and fibromatosis-like variants, metaplastic carcinomas are typically aggressive, chemoresistant, and have a high propensity for metastasis.

#### Low-Grade Adenosquamous Carcinoma

First described in 1987, low-grade adenosquamous carcinoma of the breast is a rare variant of metaplastic carcinoma defined by having both glandular and squamous differentiation embedded in a bland spindle cell background.[3–5] These tumors have low nuclear grade and, although areas may resemble tubular carcinoma, the neoplastic glands of adenosquamous carcinoma have smooth rounded contours as opposed to the characteristic angulated glands of tubular carcinoma. The amount of squamous differentiation can vary from minimal to extensive.[5] Clusters of lymphocytes in a "cannonball"-like configuration can also be seen[3] (Figure 1, A and B). Unlike other variants of metaplastic carcinoma, low-grade adenosquamous carcinoma has a favorable prognosis. A recent study has found that low-grade adenosquamous carcinomas have high rates of *PIK3CA* mutations while lacking the *TP53* mutation frequently seen in other metaplastic carcinoma



Downloaded from https://aplm.kglmeridian.com at 2026-03-11 via free access

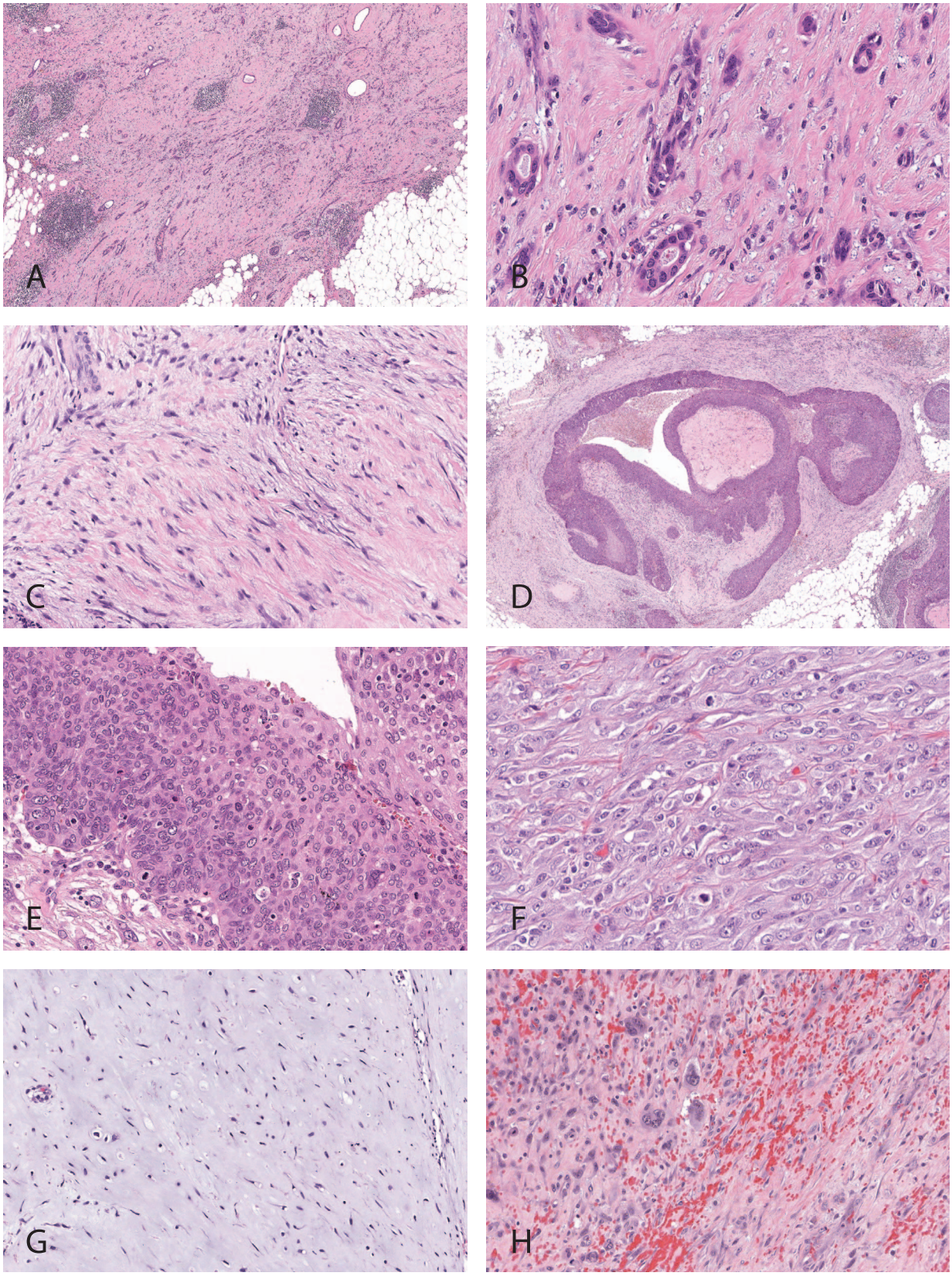


**Figure 1.** *Metaplastic carcinoma variants. A, Low-grade adenosquamous carcinoma with an infiltrative border, composed of haphazardly arranged carcinoma cell nests and glands in a collagenized stroma. Note the clusters of lymphocytes forming "cannonballs." B, Bland squamous cell nests and glands compose the tumor. C, Fibromatosis-like metaplastic carcinoma composed of low-grade spindle cells with angulated hyperchromatic nuclei in a collagenous stroma. D, Partially cystic squamous cell carcinoma. The cystic tumor is lined by a thick atypical squamous epithelium with invaginations and central hemorrhage. E, High-power magnification of the malignant squamous carcinoma cells. F, Spindle cell carcinoma featuring high-grade spindled cells without a specific pattern and with frequent mitoses. G, Carcinoma with mesenchymal differentiation. Note malignant cells within a chondroid matrix. H, Malignant giant cells in zones of hemorrhage (hematoxylin-eosin, original magnifications ×10 [A and G], ×40 [B, C, E, F, and H], and ×4 [D]).*

Downloaded from https://aplm.kglmeridian.com at 2026-03-11 via free access

variants; these molecular findings may contribute to the indolent behavior of these tumors.[6]

### Fibromatosis-like Metaplastic Carcinoma

Fibromatosis-like metaplastic carcinoma is a low-grade variant of metaplastic carcinoma that histologically resembles desmoid-type fibromatosis. These tumors are locally aggressive and have a high propensity for local recurrence, thus complete resection with clear margins is recommended. With complete resection, these tumors generally follow an indolent clinical course.[7,8]

Histologically, these tumors demonstrate a bland, spindled morphology with entrapped atypical ducts or ductal carcinoma in situ, and irregular and infiltrative borders with broad or finger-like projections into the surrounding breast parenchyma[8,9] (Figure 1, C). Focal squamous differentiation can be identified.[3] Fibromatosis-like metaplastic carcinoma has a broad differential diagnosis including desmoid-type fibromatosis, scar, nodular fasciitis, myofibroblastoma, pseudoangiomatous stromal hyperplasia, phyllodes tumor, fat necrosis, and low-grade sarcoma. Owing to the difference in prognosis and therapy, accurate diagnosis is vital. Immunohistochemical staining for high-molecular-weight cytokeratins and p63 may be helpful in this setting.[7,8]

One study examined the genomic mutational profile and genomic copy number aberration in 3 cases of fibromatosis-like metaplastic carcinoma, and demonstrated that these tumors have low genomic instability and share no copy number aberrations with other metaplastic carcinoma variants.[10]

### Squamous Cell Carcinoma

Metaplastic squamous cell carcinoma (SCC) is an aggressive form of metaplastic breast carcinoma that accounts for 0.1% of breast carcinomas. For the diagnosis, a primary SCC from a different site, such as lung or skin, must be excluded.[3,11] The etiology of metaplastic SCC is unknown; however, studies suggest that these neoplasms may arise from metaplastic squamous epithelium.[11,12] Metaplastic SCC should be suspected when atypical squamous epithelium is adjacent to atypical ductal epithelium.[3]

Histologically, metaplastic SCC is composed predominantly of cells with squamous differentiation. Other components can be observed including atypical ductal epithelium, spindle cells, chondrocytes, osteocytes, and striated muscle cells. While they can be solid, metaplastic SCCs are frequently cystic, with the cavity lined by atypical squamous cells[3,11] (Figure 1, D and E). An acantholytic variant of metaplastic SCC with a pseudoglandular appearance can be easily mistaken for an angiosarcoma.[13]

### Spindle Cell Carcinoma

Spindle cell carcinoma is an aggressive variant of metaplastic carcinoma, characterized by intermediate to highly atypical spindle cells, with areas of necrosis and evident frequent mitotic figures. Spindle cell carcinoma can have multiple architectural patterns, but the cells are typically arranged in a wavy, interlacing, and overlapping fascicular, "patternless" pattern (Figure 1, F). Focal squamous differentiation may or may not be identified.[3,14]

The differential diagnosis of spindle cell carcinoma is similar to that of fibromatosis-like metaplastic carcinoma and includes phyllodes tumor, and primary or metastatic sarcoma.[15] When present, a carcinomatous component, including invasive ductal carcinoma or ductal carcinoma in situ, is extremely useful in this differential diagnosis. As discussed below, immunostaining plays an important role in the differential diagnosis.[3,12]

While the cell of origin of metaplastic carcinoma remains unknown, some investigators have argued that this particular variant may originate from myoepithelial cells, as spindle cell carcinomas are frequently positive for at least 1 myoepithelial marker such as p63, smooth muscle actin, and CD10.[14,16]

### Carcinoma With Mesenchymal Differentiation

These aggressive tumors are composed of an admixture of differentiated mesenchymal components, including chondroid, osseous, rhabdomyoid, and rarely neuroglial elements.[3,17] This type of metaplastic carcinoma is further subclassified by the WHO into 1 of 3 categories: carcinoma with chondroid differentiation, carcinoma with osseous differentiation, and carcinoma with other types of mesenchymal differentiation.[3] These tumors are frequently large at the time of diagnosis.[17]

Histologically, carcinoma with mesenchymal differentiation may demonstrate varying patterns and combinations of mesenchymal elements. Most commonly seen is an admixture of cartilaginous and osseous differentiation. The heterologous components can show a wide spectrum of atypia, ranging from bland to overtly malignant.[15,17] Although infrequent, some tumors may demonstrate osteoclast-type giant cells, often found adjacent to zones of stromal hemorrhage[15] (Figure 1, G and H).

The differential diagnosis for carcinoma with mesenchymal differentiation depends on the metaplastic component and includes high-grade phyllodes tumor, primary breast sarcoma, extraskeletal osteosarcoma, and myoepithelial carcinoma.[15] Identification of a carcinomatous component is critical in navigating the differential diagnosis and is usually present. In cases where overt carcinoma is not identified, immunostaining is very helpful, as discussed below.[3]

## IMMUNOHISTOCHEMISTRY IS VERY HELPFUL IN THE DIAGNOSIS

Immunohistochemistry is an integral part of the diagnosis of metaplastic carcinoma. All variants of metaplastic carcinoma are almost invariably negative for estrogen and progesterone receptors, and negative for HER2/neu overexpression.[18,19] It is important to highlight that metaplastic carcinomas are positive for high-molecular-weight cytokeratins/basal cytokeratin including CK5/6 and 34βE12,[20] and may also stain with broad-spectrum cytokeratins. Another marker that is useful in the diagnosis of these tumors is p63, with high sensitivity and specificity (86.7% and 99.4%, respectively). P63 staining may be observed in both the epithelial and spindle cell components.[21] CD10 is frequently expressed in spindle cell carcinomas (94%); however, expression is seen less frequently in other variants (0%–71%).[22] CK7 shows positivity in approximately 30% to 60% of metaplastic carcinomas.[22] We would like to emphasize that in daily pathology practice, a combination of several stains (eg, cytokeratin cocktail, p63, high-molecular-weight cytokeratins) is usually needed and is extremely helpful to make an accurate diagnosis.

## METAPLASTIC BREAST CARCINOMAS HARBOR GENE MUTATIONS

Molecular studies of metaplastic carcinomas of the breast have been limited by the availability of adequate patient cohorts. Most gene expression profiling studies in breast



Downloaded from https://aplm.kglmeridian.com at 2026-03-11 via free access

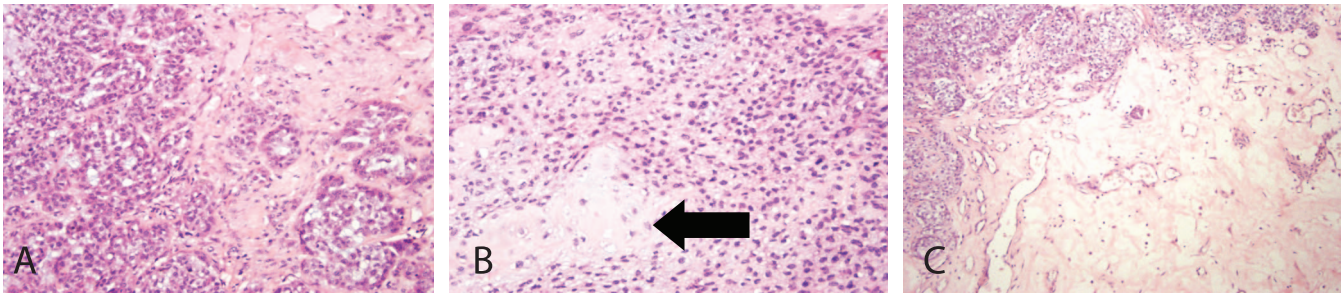


**Figure 2.** *Carcinoma with chondroid differentiation and partial response to neoadjuvant therapy. A and B, Areas of invasive ductal carcinoma (A) with focal chondroid component (arrow in [B]) in a carcinoma with chondroid differentiation. Note the highly atypical and hyperchromatic cells surrounding the chondroid areas. C, Residual carcinoma and hyalinized area of treatment effect with neovascularization (hematoxylin-eosin, original magnifications ×20 [A and B] and ×10 [C]).*

cancer often have insufficient numbers of metaplastic carcinomas to draw meaningful conclusions. It has been reported that the carcinomatous and metaplastic components demonstrate clonality,[23] suggesting a common precursor for the histologically distinct components. Recent genomic analyses have shown that metaplastic carcinoma and nonmetaplastic triple-negative breast carcinomas (TNBCs) share *TP53* mutations.[24–28] Using 27 metaplastic carcinomas, we have identified *WNT* pathway gene mutations, including *CTNNB1*, *APC*, and *CCN6/WISP3* in 25.9%, 7.4%, and 18.5% of cases, respectively.[29] Of note, subsequent studies showed that metaplastic carcinomas harbor more frequent *PI3K* and *WNT* pathway gene mutations than nonmetaplastic TNBCs.[25] This was also evident in a recent sequencing study of 28 metaplastic carcinomas including different histologic variants.[30] Interestingly, this study showed that telomerase reverse transcriptase (TERT) promoter mutations vary among subtypes, as they are common in spindle cell carcinoma and SCC (47% of tumors) but are absent in metaplastic carcinomas with chondroid mesenchymal differentiation. Taken together, these studies suggest that metaplastic carcinomas are distinct from TNBCs, and that specific histologic variants of metaplastic carcinoma have both common and unique genetic defects, which needs to be further investigated.

## NEW, PROMISING MOLECULAR ALTERATIONS IN METAPLASTIC CARCINOMA: FROM PATHOLOGY TO MOUSE MODELS, AND BACK

With the exception of low-grade adenosquamous carcinoma and fibromatosis-like metaplastic carcinoma, metaplastic breast carcinomas are more aggressive and demonstrate a higher propensity for metastasis than nonmetaplastic TNBCs.[2,31] These tumors are frequently chemoresistant, with variable responses to neoadjuvant chemotherapy[32–34] (Figure 2, A through C).

Until recently, there have been no mouse models that recapitulate human disease in which to test new approaches to therapy. Our laboratory has devoted efforts to understanding the pathobiology of these tumors and generating a useful mouse model, as critical steps in the development and testing of effective treatment and biomarkers of disease progression.

*CCN6,* also called *WISP3* (Wnt-1–induced secreted protein 3), encodes a matricellular protein involved in the maintenance of an epithelial phenotype and cell attachment to extracellular matrix. CCN6 protein is expressed in the cytoplasm of breast epithelial cells and is secreted into the extracellular medium, where it exerts regulatory rather than structural roles. We have reported that in biologically aggressive breast cancers, including metaplastic carcinomas, CCN6 levels are low.[35–38] Molecular and cell biology studies showed that low CCN6 expression in the mammary gland results in enhanced insulin-like growth factor 1 (IGF1) and bone morphogenetic protein-4 (BMP4) signaling, which induce epithelial to mesenchymal transition, invasion, and migration.[35–37,39]

To investigate whether CCN6 is directly involved in the development of aggressive breast cancer phenotypes, we decided to knock out the mouse *CCN6* gene (*Ccn6*) specifically in the mammary gland epithelium by using a Cre-Lox system and the mouse mammary tumor virus (MMTV) promoter. MMTV-cre;*Ccn6*$^{fl/fl}$ knockout mice showed developmental abnormalities in the mammary glands, and, importantly, developed breast tumors morphologically and immunophenotypically similar to human high-grade spindle and SCC metaplastic carcinomas.[38] These tumors developed in 72% of adult virgin mice and had a high incidence of distant metastasis (46%). We envision that the MMTV-cre;*Ccn6*$^{fl/fl}$ knockout model will be useful to test new drugs, doses, and schedules and help in clinical trial design specifically for patients with spindle and SCC metaplastic carcinomas.

Transcriptomic analyses of MMTV-cre;*Ccn6*$^{fl/fl}$ metaplastic carcinomas and comparison with transcriptional profiles of human metaplastic carcinomas uncovered 87 concordantly deregulated genes. Of these, *IGF2BP2* and *HMGA2* are the 2 top upregulated genes in both human and mouse metaplastic carcinomas.[38] IGF2BP2 (insulin-like growth factor 2 mRNA-binding protein 2 [IMP2]) and HMGA2 (high-mobility group AT-Hook 2) are oncofetal proteins that participate in embryonic development and are reduced in normal adult tissues.[40,41] In breast cancer, *IGF2BP2* overexpression is associated with decreased cell adhesion and migration.[41] Increased *HMGA2* expression is associated with a migratory phenotype, an epithelial to mesenchymal transition, and worse outcome in breast cancer.[42] *IGF2BP2* gene transcription and protein expression are dependent on HMGA2 protein binding to an AT-rich region of *IGF2BP2*'s first intron in its DNA sequence.[43] We recently showed that downregulation of *CCN6* leads to increased *IGF2BP2* and *HMGA2* expression in metaplastic carcinoma. Immunohistochemistry analysis of 31 metaplastic carcinomas showed that spindle and squamous metaplastic carcinomas have reduced CCN6 and upregulated IGF2BP2 and/or HMGA2 expression. Additionally, treatment of tumor-bearing

Downloaded from https://aplm.kglmeridian.com at 2026-03-11 via free access

MMTV-cre;*Ccn6*$^{fl/fl}$ mice with recombinant CCN6 protein led to smaller mammary tumors with reduced expression of IGF2BP2 and HMGA2 protein expression as compared to control treated mice. Collectively, these studies suggest that CCN6, IGF2BP2, and HMGA2 signaling pathway may play a functional role in the development of spindle and squamous metaplastic carcinomas, with promise as biomarkers and potential targets.[44]

## CONCLUSIONS

Metaplastic breast carcinomas are a heterogeneous group of malignancies that can exhibit multiple morphologies. The differential diagnosis is broad. However, the identification of an atypical epithelial or carcinomatous component and immunohistochemical evidence of carcinomatous differentiation are extremely helpful in the differential diagnosis. Recent genetic and molecular studies are shedding light into the crucial determinants of metaplastic carcinomas and offer a novel mouse model for high-grade spindle and squamous tumors. Future investigations aimed at understanding the link between the phenotypic diversity of metaplastic carcinomas, gene and protein expression patterns, and their relationship with biological behavior will be important to develop specific and effective therapies.

### References


1. Oberman HA. Metaplastic carcinoma of the breast: a clinicopathologic study of 29 patients. *Am J Surg Pathol*. 1987;11(12):918–929.
2. Rakha EA, Tan PH, Varga Z, et al. Prognostic factors in metaplastic carcinoma of the breast: a multi-institutional study. *Br J Cancer*. 2015;112(2):283–289.
3. Reis-Filho JS, Lakhani SR, Gobbi H, Sneige N. Metaplastic carcinoma. *WHO Classification of Tumours of the Breast*. 4th ed. Lyon, France: International Agency for Research on Cancer; 2012;48–52. *World Health Organization Classification of Tumours*; vol 4.
4. Tan QT, Chuwa EW, Chew SH, Lim-Tan SK, Lim SH. Low-grade adenosquamous carcinoma of the breast: a diagnostic and clinical challenge. *Int J Surg*. 2015;19:22–26.
5. Rosen PP, Ernsberger D. Low-grade adenosquamous carcinoma: a variant of metaplastic mammary carcinoma. *Am J Surg Pathol*. 1987;11(5):351–358.
6. Bataillon G, Fuhrmann L, Girard E, et al. High rate of PIK3CA mutations but no TP53 mutations in low-grade adenosquamous carcinoma of the breast. *Histopathology*. 2018;73(2):273–283.
7. Dwyer JB, Clark BZ. Low-grade fibromatosis-like spindle cell carcinoma of the breast. *Arch Pathol Lab Med*. 2015;139(4):552–557.
8. Rungta S, Kleer CG. Metaplastic carcinomas of the breast: diagnostic challenges and new translational insights. *Arch Pathol Lab Med*. 2012;136(8):896–900.
9. Gobbi H, Simpson JF, Borowsky A, Jensen RA, Page DL. Metaplastic breast tumors with a dominant fibromatosis-like phenotype have a high risk of local recurrence. *Cancer*. 1999;85(10):2170–2182.
10. Takano EA, Hunter SM, Campbell IG, Fox SB. Low-grade fibromatosis-like spindle cell carcinomas of the breast are molecularly exiguous. *J Clin Pathol*. 2015;68(5):362–367.
11. Cha N, Wang S, Lv M, et al. Breast metaplastic squamous cell carcinoma diagnosed with fine needle and core biopsy: a case study. *Am J Case Rep*. 2018;19:203–206.
12. Huws AM, Semkin L, Moalla A, Udayasankar S, Holt SDH, Sharaiha YM. Primary squamous cell carcinoma of the breast in association with Zuska's disease. *Breast Cancer*. 2018;25(3):365–369.
13. Eusebi V, Lamovec J, Cattani MG, Fedeli F, Millis RR. Acantholytic variant of squamous-cell carcinoma of the breast. *Am J Surg Pathol*. 1986;10(12):855–861.
14. Zhu H, Li K, Dong DD, et al. Spindle cell metaplastic carcinoma of breast: a clinicopathological and immunohistochemical analysis. *Asia Pac J Clin Oncol*. 2017;13(2):e72–e78.
15. Cheah AL, Billings SD, Rowe JJ. Mesenchymal tumours of the breast and their mimics: a review with approach to diagnosis. *Pathology*. 2016;48(5):406–424.
16. Leibl S, Gogg-Kammerer M, Sommersacher A, Denk H, Moinfar F. Metaplastic breast carcinomas: are they of myoepithelial differentiation: immunohistochemical profile of the sarcomatoid subtype using novel myoepithelial markers. *Am J Surg Pathol*. 2005;29(3):347–353.
17. Salemis NS. Metaplastic carcinoma of the breast with mesenchymal differentiation (carcinosarcoma): a unique presentation of an aggressive malignancy and literature review. *Breast Dis*. 2018;37(3):169–175.
18. Abouharb S, Moulder S. Metaplastic breast cancer: clinical overview and molecular aberrations for potential targeted therapy. *Curr Oncol Rep*. 2015;17(3):431.
19. Pang J, Toy KA, Griffith KA, et al. Invasive breast carcinomas in Ghana: high frequency of high grade, basal-like histology and high EZH2 expression. *Breast Cancer Res Treat*. 2012;135(1):59–66.
20. Adem C, Reynolds C, Adlakha H, Roche PC, Nascimento AG. Wide spectrum screening keratin as a marker of metaplastic spindle cell carcinoma of the breast: an immunohistochemical study of 24 patients. *Histopathology*. 2002;40(6):556–562.
21. Koker MM, Kleer CG. p63 expression in breast cancer: a highly sensitive and specific marker of metaplastic carcinoma. *Am J Surg Pathol*. 2004;28(11):1506–1512.
22. Rakha EA, Coimbra ND, Hodi Z, Juneinah E, Ellis IO, Lee AH. Immunoprofile of metaplastic carcinomas of the breast. *Histopathology*. 2017;70(6):975–985.
23. Zhuang Z, Lininger RA, Man YG, Albuquerque A, Merino MJ, Tavassoli FA. Identical clonality of both components of mammary carcinosarcoma with differential loss of heterozygosity. *Mod Pathol*. 1997;10(4):354–362.
24. Hennessy BT, Gonzalez-Angulo AM, Stemke-Hale K, et al. Characterization of a naturally occurring breast cancer subset enriched in epithelial-to-mesenchymal transition and stem cell characteristics. *Cancer Res*. 2009;69(10):4116–4124.
25. Ng CKY, Piscuoglio S, Geyer FC, et al. the landscape of somatic genetic alterations in metaplastic breast carcinomas. *Clin Cancer Res*. 2017;23(14):3859–3870.
26. Badve S, Dabbs DJ, Schnitt SJ, et al. Basal-like and triple-negative breast cancers: a critical review with an emphasis on the implications for pathologists and oncologists. *Mod Pathol*. 2011;24(2):157–167.
27. Turner NC, Reis-Filho JS. Basal-like breast cancer and the BRCA1 phenotype. *Oncogene*. 2006;25(43):5846–5853.
28. Turner NC, Reis-Filho JS, Russell AM, et al. BRCA1 dysfunction in sporadic basal-like breast cancer. *Oncogene*. 2007;26(14):2126–2132.
29. Hayes MJ, Thomas D, Emmons A, Giordano TJ, Kleer CG. Genetic changes of Wnt pathway genes are common events in metaplastic carcinomas of the breast. *Clin Cancer Res*. 2008;14(13):4038–4044.
30. Krings G, Chen YY. Genomic profiling of metaplastic breast carcinomas reveals genetic heterogeneity and relationship to ductal carcinoma. *Mod Pathol*. 2018;31(11):1661–1674.
31. Song Y, Liu X, Zhang G, et al. Unique clinicopathological features of metaplastic breast carcinoma compared with invasive ductal carcinoma and poor prognostic indicators. *World J Surg Oncol*. 2013;11:129.
32. Al-Hilli Z, Choong G, Keeney MG, et al. Metaplastic breast cancer has a poor response to neoadjuvant systemic therapy. *Breast Cancer Res Treat*. 2019;176(3):709–716.
33. Samoon Z, Beg M, Idress R, Jabbar AA. Survival and treatment outcomes of metaplastic breast carcinoma: single tertiary care center experience in Pakistan. *Indian J Cancer*. 2019;56(2):124–129.
34. Han M, Salamat A, Zhu L, et al. Metaplastic breast carcinoma: a clinical-pathologic study of 97 cases with subset analysis of response to neoadjuvant chemotherapy. *Mod Pathol*. 2019;32(6):807–816.
35. Kleer CG, Zhang Y, Pan Q, Merajver SD. WISP3 (CCN6) is a secreted tumor-suppressor protein that modulates IGF signaling in inflammatory breast cancer. *Neoplasia*. 2004;6(2):179–185.
36. Huang W, Zhang Y, Varambally S, et al. Inhibition of CCN6 (Wnt-1-induced signaling protein 3) down-regulates E-cadherin in the breast epithelium through induction of snail and ZEB1. *Am J Pathol*. 2008;172(4):893–904.
37. Kleer CG, Zhang Y, Pan Q, et al. WISP3 is a novel tumor suppressor gene of inflammatory breast cancer. *Oncogene*. 2002;21(20):3172–3180.
38. Martin EE, Huang W, Anwar T, et al. MMTV-cre;Ccn6 knockout mice develop tumors recapitulating human metaplastic breast carcinomas. *Oncogene*. 2017;36(16):2275–2285.
39. Pal A, Huang W, Li X, Toy KA, Nikolovska-Coleska Z, Kleer CG. CCN6 modulates BMP signaling via the Smad-independent TAK1/p38 pathway, acting to suppress metastasis of breast cancer. *Cancer Res*. 2012;72(18):4818–4828.
40. Dai N, Ji F, Wright J, Minichiello L, Sadreyev R, Avruch J. IGF2 mRNA binding protein-2 is a tumor promoter that drives cancer proliferation through its client mRNAs IGF2 and HMGA1. *eLife*. 2017;6:e27155.
41. Li Y, Francia G, Zhang JY. p62/IMP2 stimulates cell migration and reduces cell adhesion in breast cancer. *Oncotarget*. 2015;6(32):32656–32668.
42. Morishita A, Zaidi MR, Mitoro A, et al. HMGA2 is a driver of tumor metastasis. *Cancer Res*. 2013;73(14):4289–4299.
43. Cleynen I, Brants JR, Peeters K, et al. HMGA2 regulates transcription of the Imp2 gene via an intronic regulatory element in cooperation with nuclear factor-kappaB. *Mol Cancer Res*. 2007;5(4):363–372.
44. McMullen ER, Gonzalez ME, Skala SL, et al. CCN6 regulates IGF2BP2 and HMGA2 signaling in metaplastic carcinomas of the breast. *Breast Cancer Res Treat*. 2018;172(3):577–586.


Downloaded from https://aplm.kglmeridian.com at 2026-03-11 via free access